

APPENDICULAR SKELETON LAB LOWER LIMB VIDEO RECORDING LINKS AND TERMINOLOGY LIST

Dr. Lisa Brinn

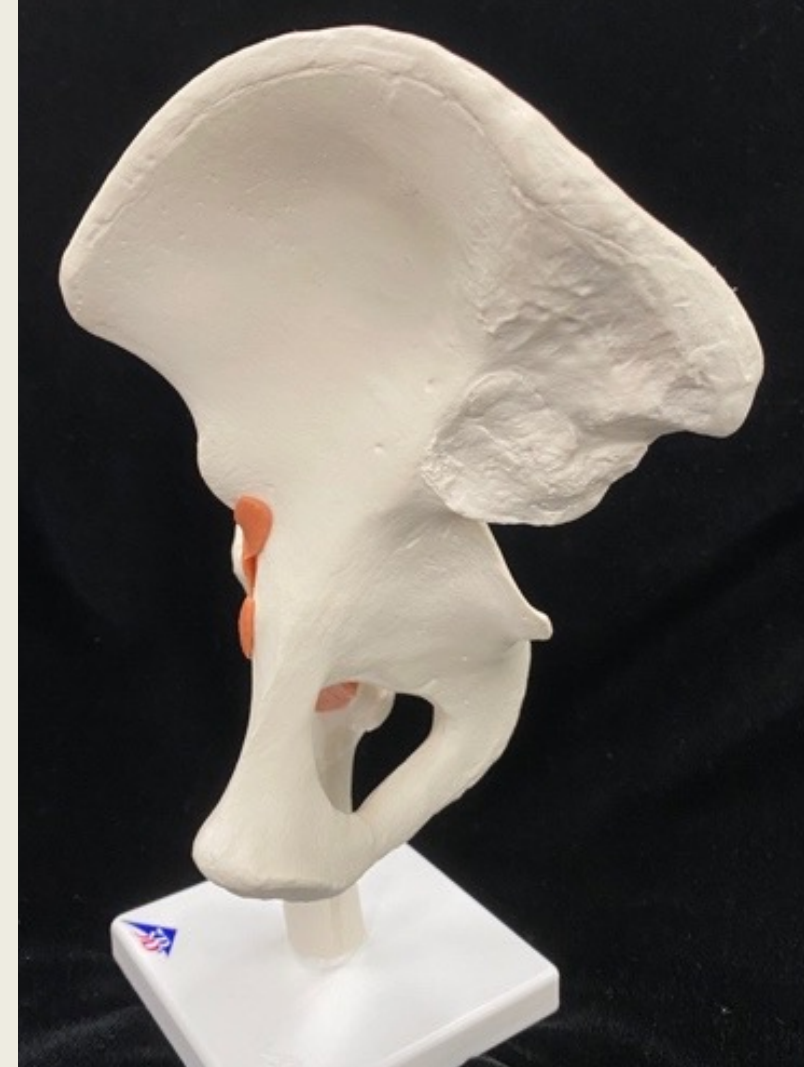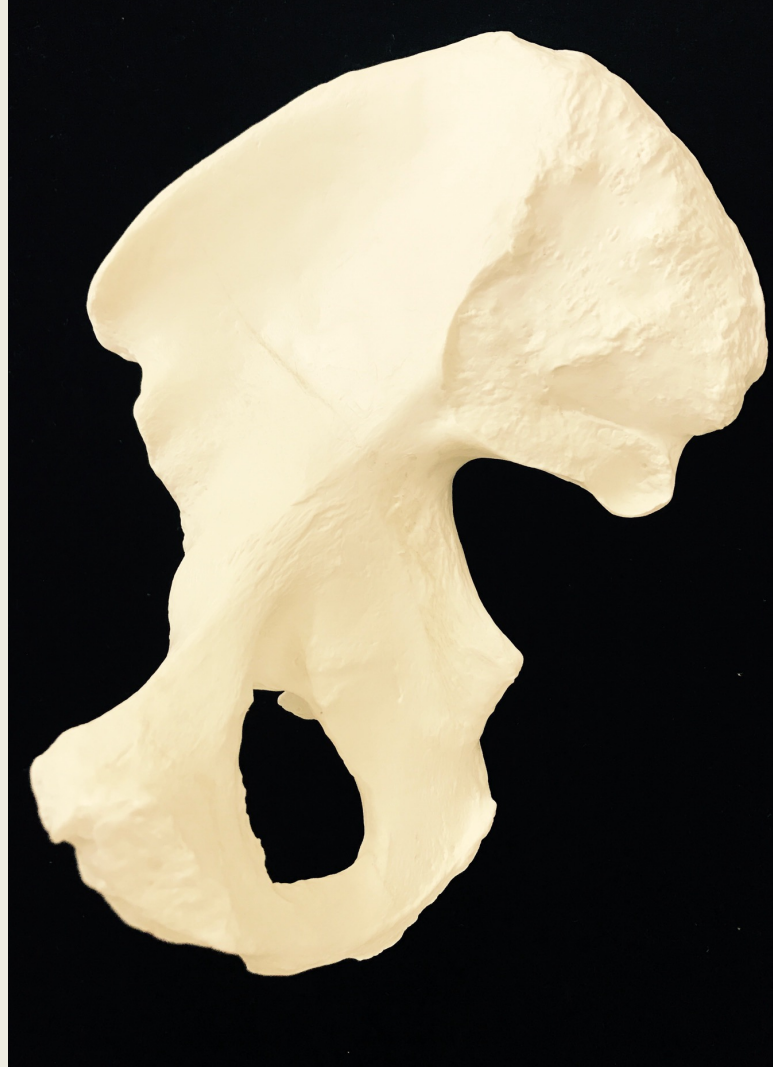
Video Recording Links for Lower Limb

- [Module 6 Exercise 14 Video Pelvic Girdle](#)
- [Module 6 Exercise 15 Video Femur](#)
- [Module 6 Exercise 15 Video Tibia](#)
- [Module 6 Exercise 15 Video Fibula](#)
- [Module 6 Exercise 15 Video Ankle, Foot, Digits](#)

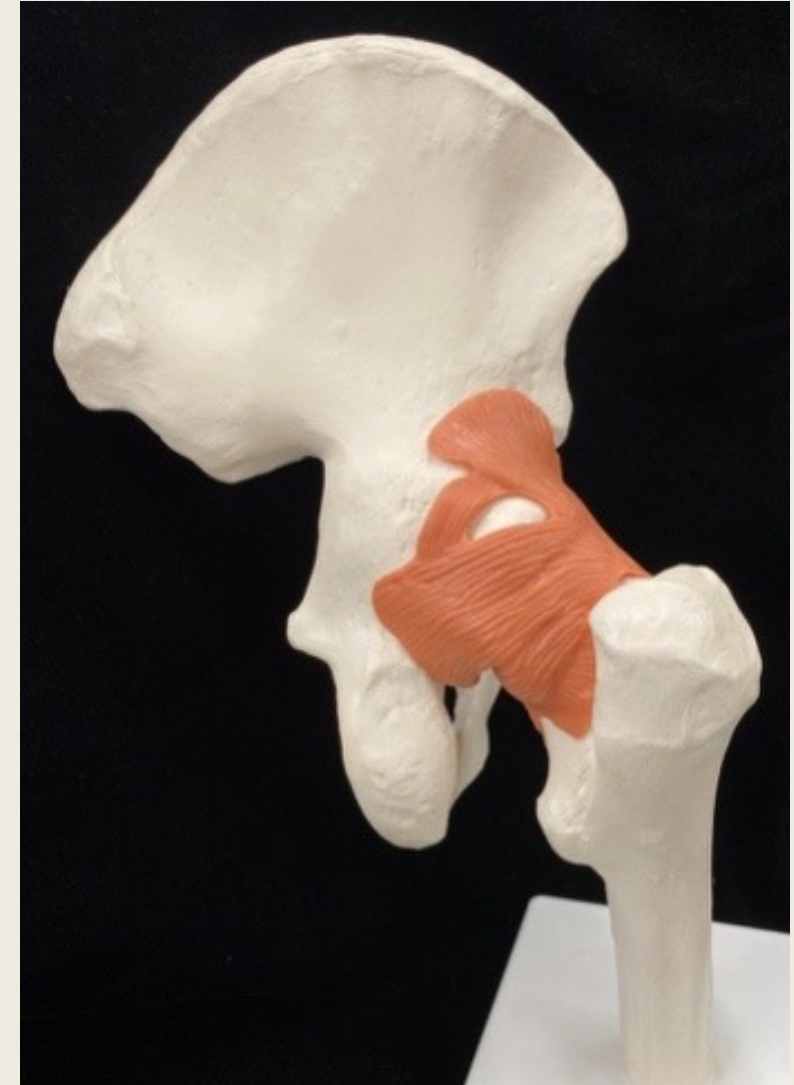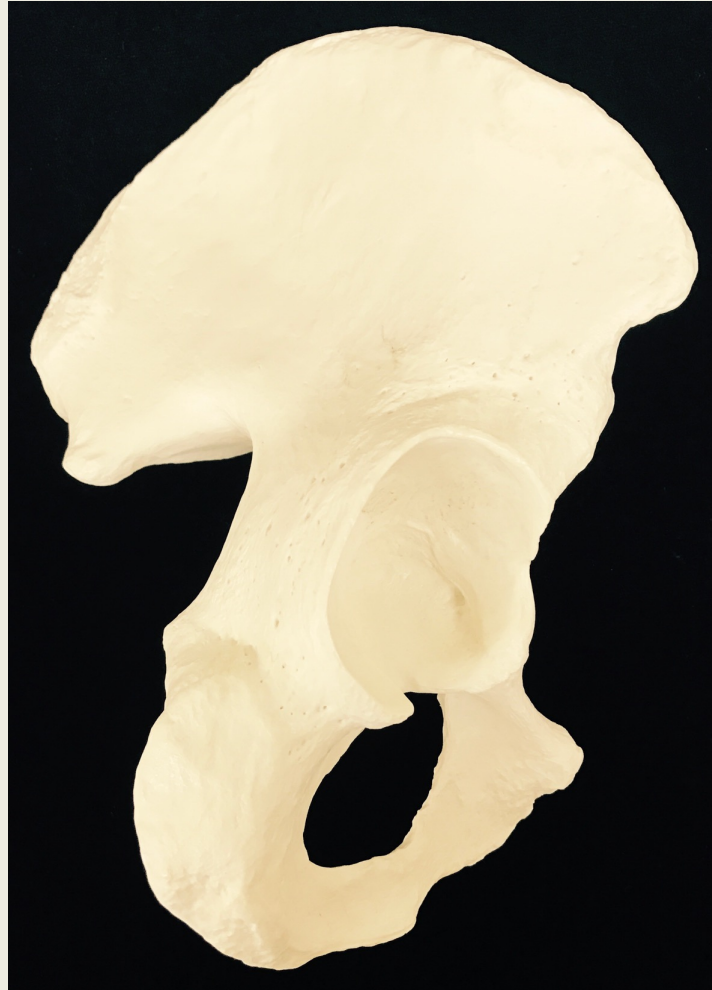Pelvic Girdle

Bone	Bone Features
Coxal bone/os coxa	
• Ilium	<ul style="list-style-type: none">○ iliac crest○ greater sciatic notch○ iliac fossa
• Pubis	<ul style="list-style-type: none">○ pubic symphysis
• Ischium	<ul style="list-style-type: none">○ lesser sciatic notch○ ischial tuberosity○ ischial spine
Shared features:	<ul style="list-style-type: none">● acetabulum (all three)● obturator foramen (ischium and pubis)

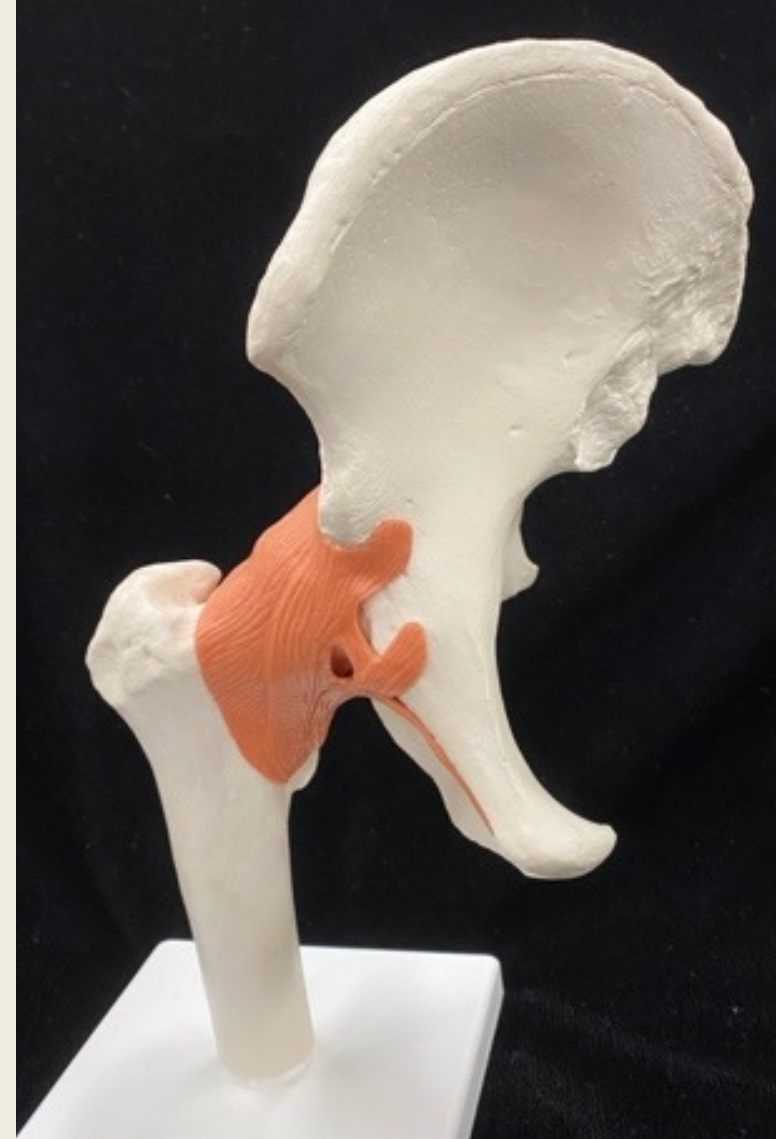
Coxal Bone or Os Coxa or Pelvic Bone medial view



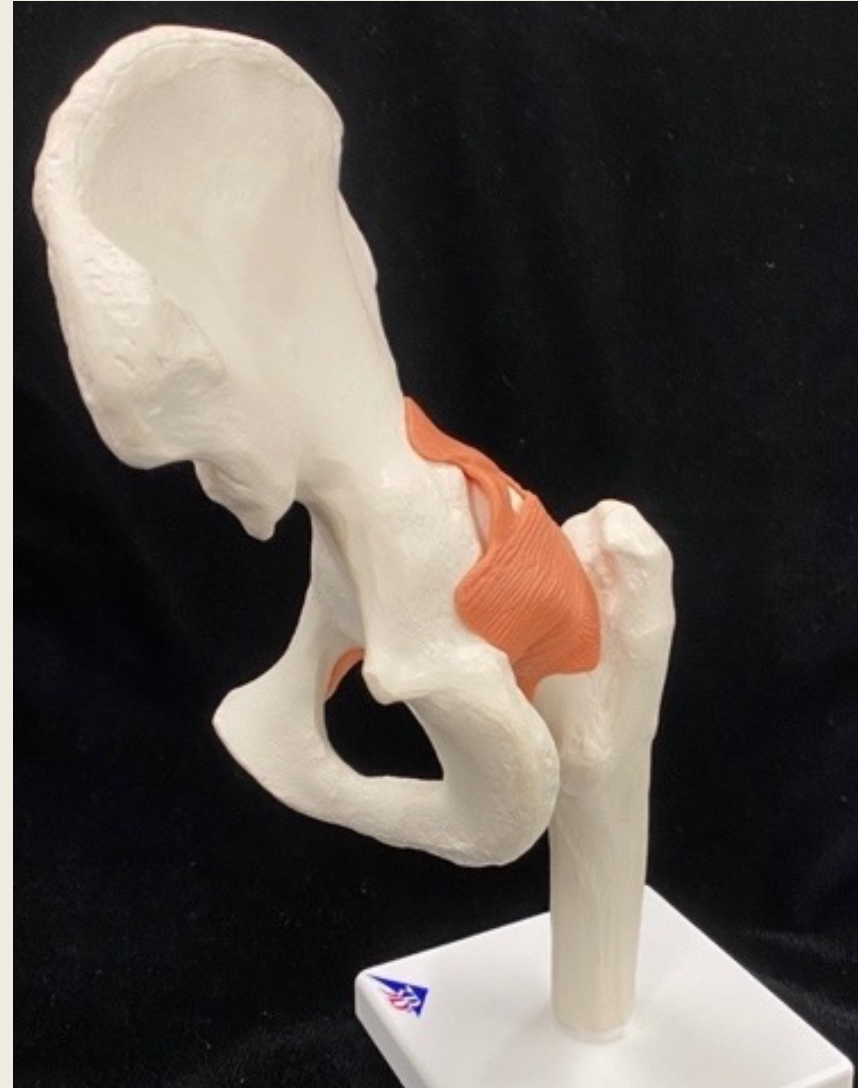Coxal Bone or Os Coxa or Pelvic Bone posterolateral view



Coxal Bone or Os Coxa or Pelvic Bone anterior view



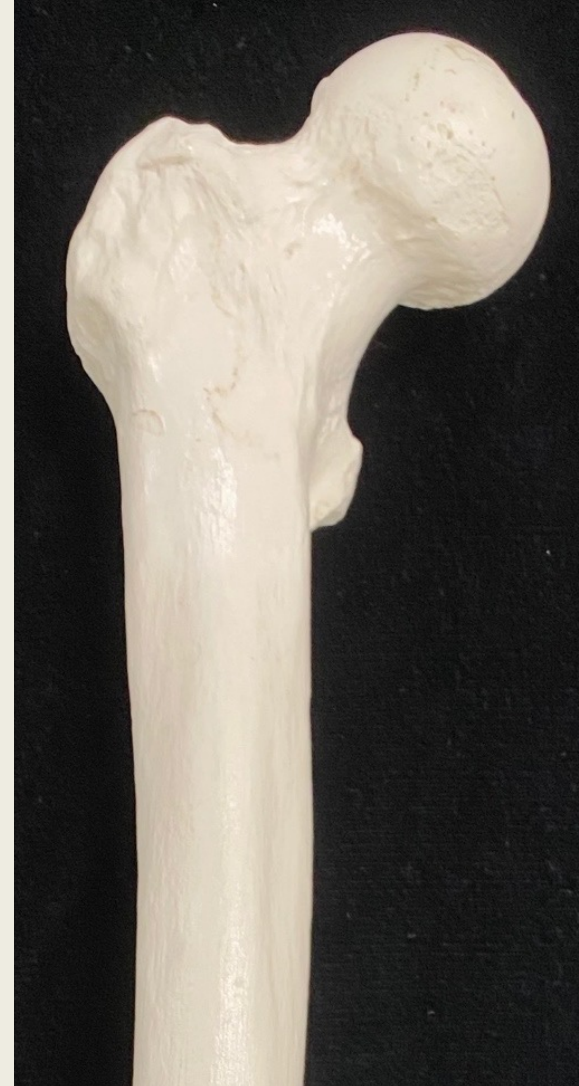Coxal Bone or Os Coxa or Pelvic Bone posteromedial view



Thigh

Bone	Bone Features
Femur	<ul style="list-style-type: none">• head• neck• greater trochanter• lesser trochanter• gluteal tuberosity• linea aspera• patellar surface• lateral condyle• medial condyle• lateral epicondyle• medial epicondyle

Femur anterior view



Proximal End

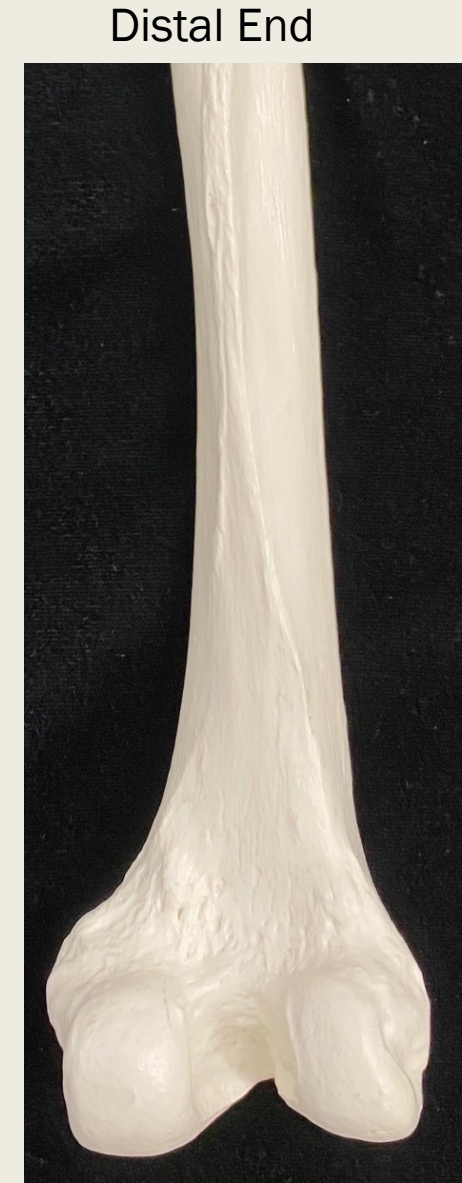Distal End



Femur posterior view



Proximal End

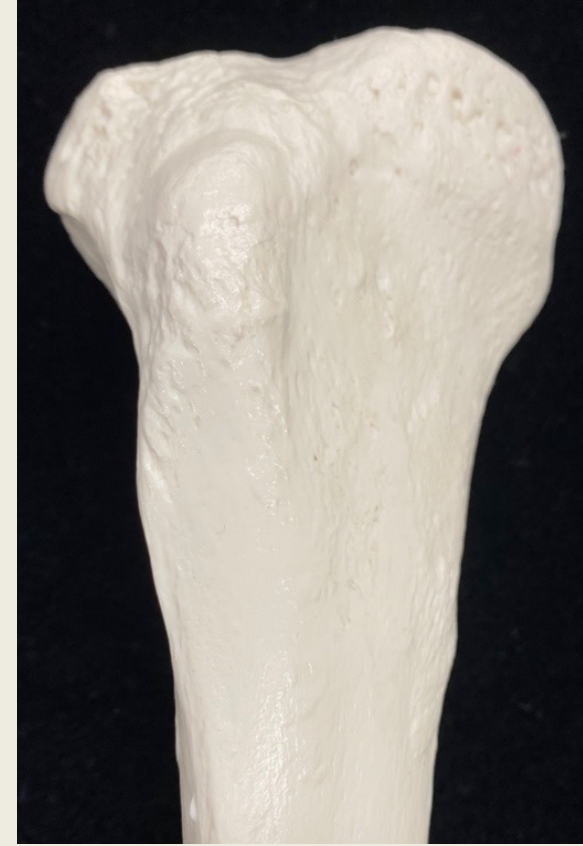

Distal End

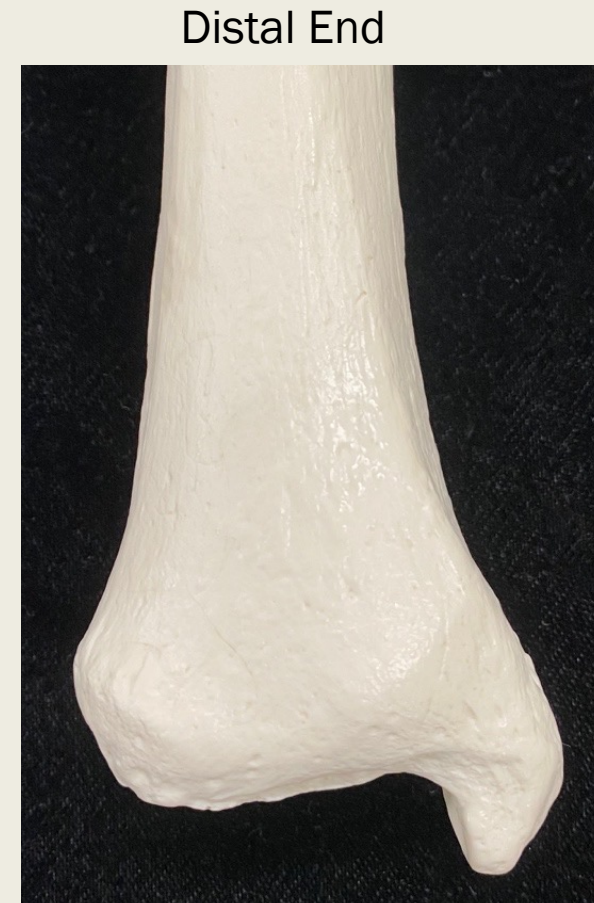Leg

Bone	Bone Features
Tibia	<ul style="list-style-type: none">• medial condyle• tibial tuberosity• anterior tibial margin• medial malleolus
Fibula	<ul style="list-style-type: none">• head• lateral malleolus• lateral condyle
Patella	

Tibia anterior view

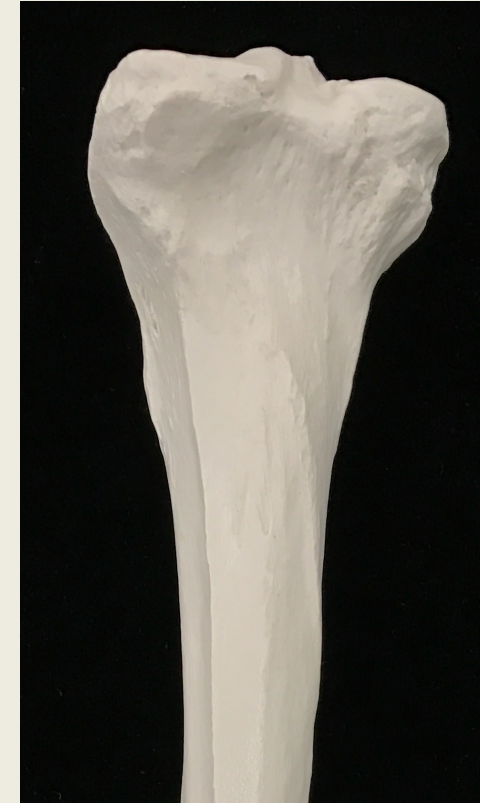
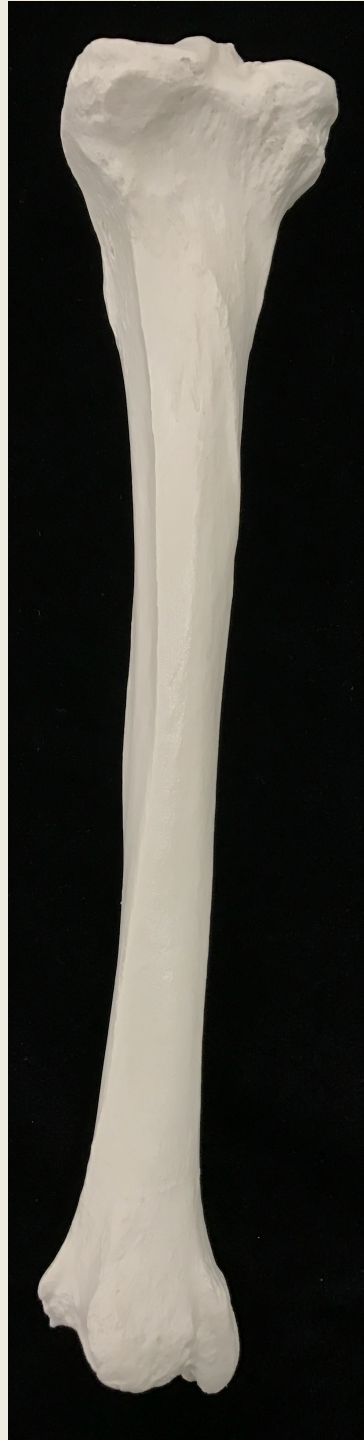
Proximal End



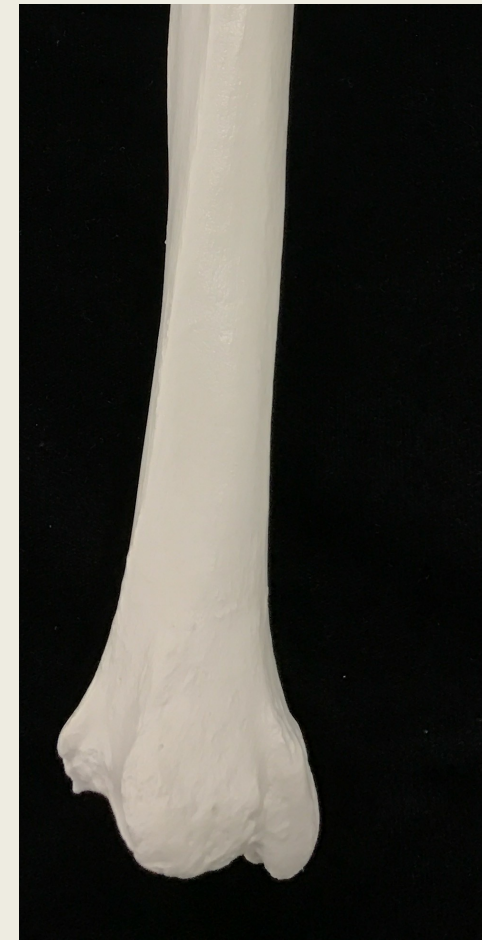Distal End

Tibia posterior view

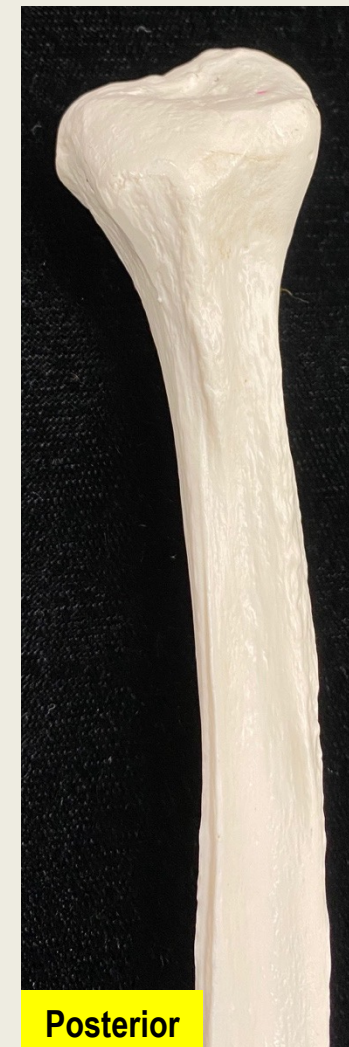
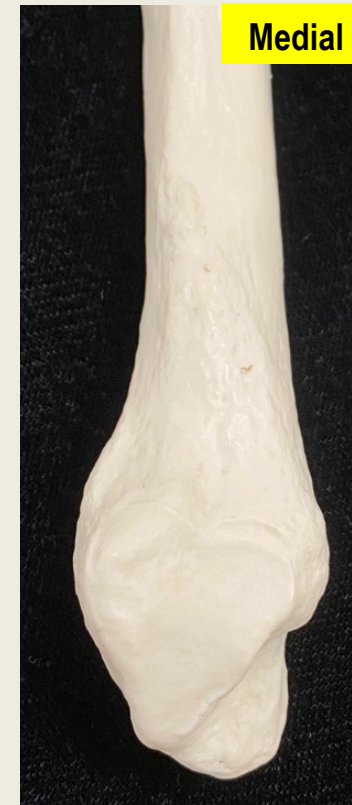
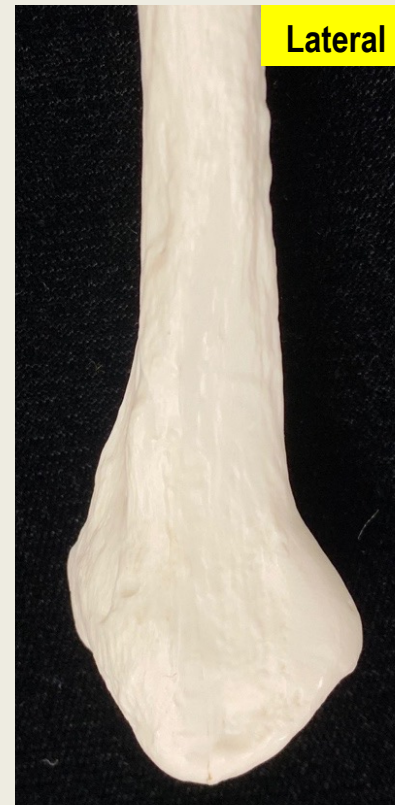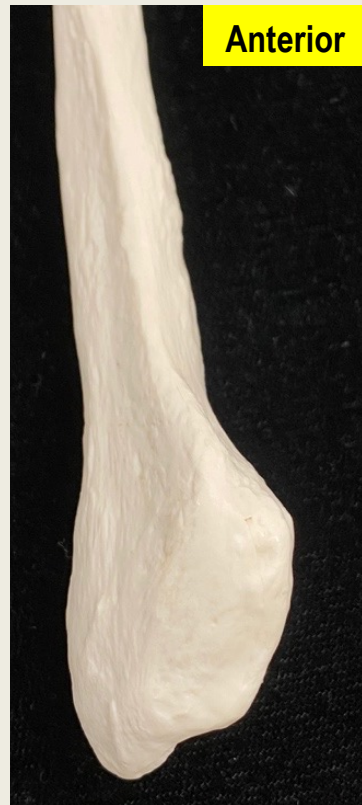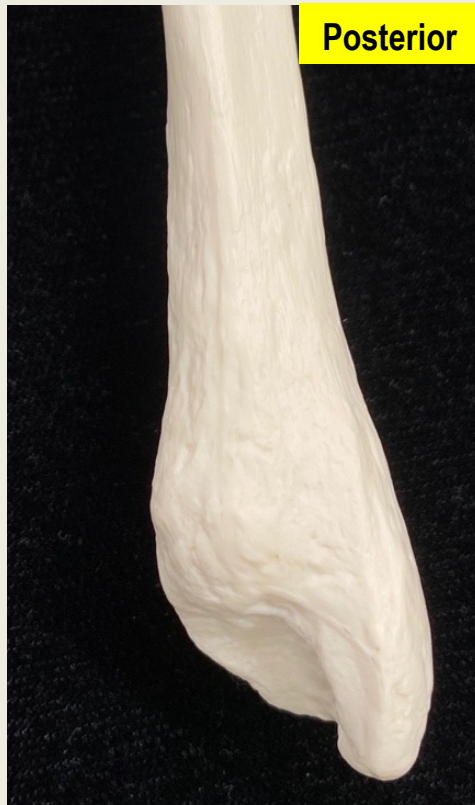Proximal End

Distal End



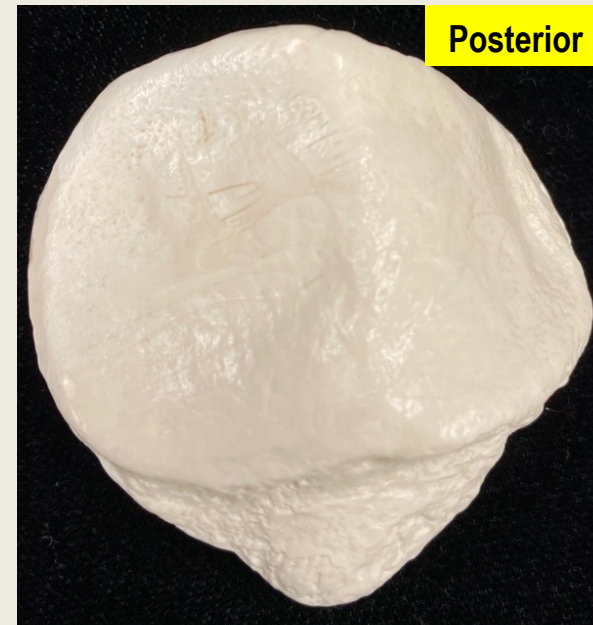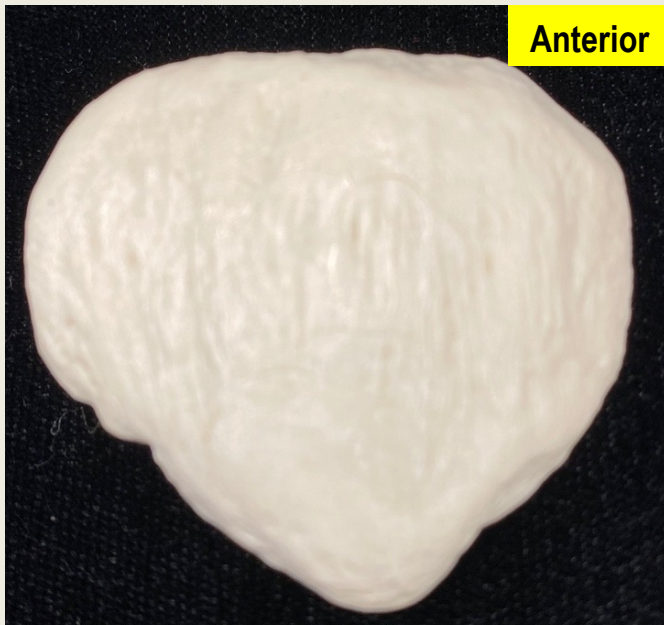Fibula all views



Distal End

Patella

anterior and posterior view



Ankle and Foot

Bone	Mnemonic:
Tarsals <ul style="list-style-type: none"> • Talus • Calcaneus • Navicular • Cuneiforms <ul style="list-style-type: none"> ○ Medial ○ Intermediate ○ Lateral • Cuboid 	<u>T</u> iger <u>C</u> ub <u>N</u> eeds <u>MILC</u> <u>T</u> alus <u>C</u> alcaneus <u>N</u> avicular <u>M</u> edial cuneiform <u>I</u> ntermediate cuneiform <u>L</u> ateral cuneiform <u>C</u> uboid
Hand and digits <ul style="list-style-type: none"> • Metatarsals (I-V) • Phalanges <ul style="list-style-type: none"> ○ Proximal phalanx ○ Middle phalanx ○ Distal phalanx • Hallux 	

Ankle and Foot superior and inferior views

